

Occurrence of *Demodex Folliculorum* in Alopecia Androgenetica

Madhumita Barua, Shukla Das, Rumpa Saha

Department of Microbiology, University College of Medical Sciences & Guru Teg Bahadur Hospital, Dilshad Garden, New Delhi -110095.

Accepted on 22 August 2012

Abstract

Alopecia is one of the most common dermatological disorders, which is of great concern recently. The probable role of *Demodex folliculorum* as an inflammatory activator resulting in such condition has been reported rarely. Here, we describe a case of an adult male who presented with patchy hair loss for one month suggestive of alopecia androgenetica. Microbiological examination (wet mount) preparation revealed the presence of an ectoparasite: *Demodex folliculorum*. This infiltrates the sebaceous glands of hair follicles and causes an immune response and inflammation of the surrounding tissue, resulting in hair fall. The patient was put on 1% gamaderm lotion and advised to improve hair care practices.

Key words: *Demodex folliculorum*, Androgenetic alopecia

Introduction

Alopecia is the absence or slowing of hair growth or loss of hair in an area from the head or body where hair formerly grew, sometimes to the extent of baldness. Unlike the common cosmetic depilation of body hair, alopecia tends to be involuntary and unwelcome, e.g., androgenic alopecia. This is one of the common dermatological disorders, affecting both males and females after the age of 20, and is of concern due to its psychosocial impact. Androgenetic alopecia occurs in people who are apparently healthy and have no skin disorder. Initial presentation most commonly occurs in the late teenage years, early childhood, or young adulthood, but can happen with people of all ages¹.

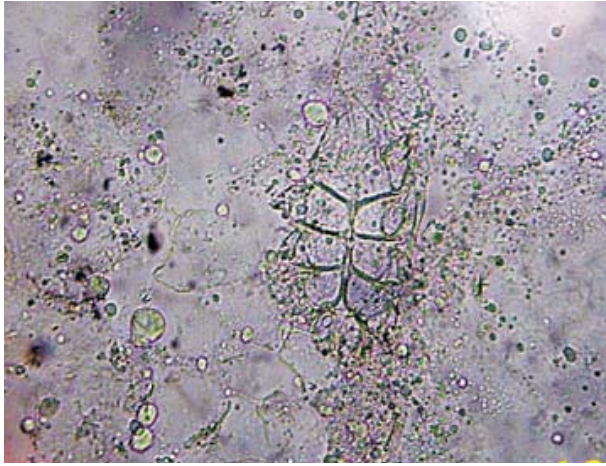
A variety of genetic and environmental factors are likely to play a role in causing alopecia. Although researchers are studying risk factors that may contribute to this condition, most of these factors remain unknown. Researchers have determined that this form of hair loss is related to hormones called androgens, particularly dihydrotestosterone (DHT)². Several other etiological factors included physical damage to the hair shaft or follicles, autoimmune disorder, emotional stress, microbial flora and heredity. One such etiological agent, demodex mite, can be present in usual conditions; however, various studies have shown its association with alopecia. Probable mechanism is by infiltrating the sebaceous gland of hair follicles, causing an immune response and inflammation of the surrounding tissue³. [Here, we report a case of alopecia androgenetica in an adult patient] n.p. caused by *Demodex folliculorum*.

Corresponding Author:

Madhumita Barua, B-78/S-1, Bharat Apartment, Rampuri, Surya Nagar, Gaziabad, Uttar Pradesh- 201011.

E-mail: barua_madhumita@yahoo.co.in

Figure 1: 10% KOH mount of scalp scrapping showed 0.5mm long adult mite, *Demodex folliculorum* ($\times 400$ magnification)



Case history

A 32-year-old male patient, belonging to socio-economically able family and residing in the close vicinity of Guru Teg Bahadur Hospital, Delhi, reported to the outpatient department of Dermatology of the hospital. He presented with cosmetic complaints of hair loss on right parietal region of scalp. He was diagnosed with alopecia androgenetica and was referred to the Department of Microbiology to rule out any fungal etiology.

Scrupulous scalp scrapping was taken from the affected area by the laboratory technician and the scrapped material was mounted in 10% KOH preparation and examined under 10X and then 40X for any fungal element. While scanning the slide an ectoparasite, dissimilar to louse but close to mite was absorbed. However, after proper viewing, it was identified as demodex mite. The adult parasite was approximately 0.5mm long with a semitransparent elongated body with two visible fused segments. The body appeared scaly with a small conical mouth part. Body also exhibited 8 short segmented legs. There was no fungal element identified in KOH mount. A detailed history and a second sample were taken from the patient and, keeping the etiology in mind, few hair were plucked with the hair bulb intact. The patient gave a history of nevus sebaceous in the affected area of scalp ten years

back, for which he got operated then, after which it remained asymptomatic. However, during the last one month, he observed that the alopecic area caused by surgery had increased significantly, involving a major area of the right parietal region. There was no positive family history of alopecia or any other significant history of drug intake.

On examination the hair appeared greasy. There were no signs of inflammation and itching was not a complaint expressed by the patient. There was a definite history of daily hair oiling and infrequent hair washing by the patient. There were no similar complaints presented in any other part of the body. The second scalp scraping was also positive for the similar parasite, demodex. Moreover, a hair bulb was identified harboring the ectoparasite. This finding suggests a strong association of demodex mite with alopecia in our case.

Discussion

Alopecia, a disorder of cosmetic importance, is the most common cause of hair loss and has multifactorial etiology^{1, 2}. Indirect role of demodex by inducing inflammation in the scalp in alopecia androgenetica pathogenesis has been suggested in many studies³. Demodex is a genus of tiny parasitic mites, an obligatory human ectoparasite, that lives in or near pilosebaceous unit of hair. It has been identified as the smallest arthropod. Two species living on humans have been identified- *Demodex folliculorum* and *Demodex brevis*- having wider distribution in the scalp and body respectively⁴. Thus, according to the presentation of the patient the species was identified as *Demodex folliculorum*. The adult mites are between 0.3mm- 0.4mm long with *D. brevis* slightly shorter than *D. folliculorum*. The body is elongated with scales required for anchoring itself on the hair follicle. Mouth parts of the mite assist in eating skin-cells and oil which accumulate in the hair follicle. It does not have an excretory orifice. The speed of mite traveling around the hair follicle is 8- 16cm/ hr, especially at night. Male is slightly longer than female with a total life span of the adult mite extending to a

few weeks. Fertilization of male and female mite at the hair follicle generates eggs in the sebaceous glands. Larval form can be differentiated by the number of legs (6 pairs) from the adult⁴. The role of this ectoparasite in disorders such as rosacea, acarica blepharitis, pityriasis follicularis, pustular folliculitis and in skin lesions of immunocompromised patients has been considered^{5,6}. The demodex - alopecia association can be related as the sebaceous glands of alopecia-affected hair follicles become larger and more active, producing oil at a faster rate under the influence of dihydrotestosterone (DHT), and thus follicles provide ambient environment for demodex. This concept also explains the presence of greasy hair in the patients, as seen in this case. Demodex mite has an immunocative lipase⁷ possibly responsible for the induction of inflammation, hair follicle exhaustion and, ultimately, the shift of the hair cycle from anagen phase to telogen⁸.

The demonstration of such ectoparasite association with human infection may at times remain undiagnosed and unreported due to the lack of proper specimen collection and skilled observation by the personnel. This can result in inaccurate management of such cases which may be relevant in the strata of population attending the hospital outpatient departments. A study has suggested more aggressive method such as biopsy for more accurate diagnosis in comparison to scalp skin scraping⁹.

Treatment of such cases is possible by using ectoparasiticides drugs known as mitaban⁴. Dermatologists prescribed gamaderm 1% lotion, to be applied topically in this case patient. However, improved nutrition, healthy practice of hair care and checking for other immune-system suppressing diseases are also recommended.

According to our finding, the probable relationship between androgenetic alopecia and

demodex infestation eriets. However, more comprehensive studies on ecologic and underlying host immunological response to demodex infestation and occurrence of alopecia are recommended.

References

1. Zari J, Abdolmajid F, Masood M, Vaheed M, Yalda N. Evaluation of the relationship with androgenetic alopecia and demodex infestation. *Indian J Dermatol* 2008; 53(2): 64-7.
2. Mahe YF, Michelet JF, Billoni N, Jarrousse F, Buan B, Commo S, et al . Androgenetic alopecia and microinflammation. *Int J Dermatol* 2000; 39: 576-84.
3. Forton F. Demodex - associated folliculitis. *Am J Dermatopathol* 1998; 20: 536-7.
4. Demodex. Available from: http://www.beautymagonline.com/pages/demodex_folliculorum.htm
5. Georgala S, Katoulis AC, Kylafis GD, Koumantaki-Mathioudaki E, Georgala C, Aroni K. Increased density of Demodex follicularum and evidence of delayed hypersensitivity reaction in subjects with papulo pustular Rosacea. *J Eur Acad Dermatol Venereol* 2001; 15: 441-4.
6. Aydingoz IE, Dervent B, Guney D. Demodex follicularum in pregnancy. *Int J Dermatol* 2000; 39: 743-5.
7. Jimenez-Acosta F, Planas L, Penneys N. Demodex mites contain immuno reactive lipase. *Arch Dermatol* 1989; 125: 1436-7.
8. Akilor OE, Mumcuoglu KY. Association between human demodicosis and HLA classes. *Clin Exp Dermatol* 2003; 28: 70-3.
9. Vollmer RT. Demodex-associated folliculitis. *Am J Dermatopathol* 1996; 18: 589-91.